

EP CASE REPORT

Interpolated Purkinje potentials recorded at a successful ablation site of a fascicular premature ventricular contraction during sinus rhythm

Taihei Itoh*, Masaomi Kimura, Yuji Ishida, and Hirofumi Tomita

Department of Cardiology, Hirosaki University Graduate School of Medicine, 5 Zaifu-cho, Hirosaki, Aomori 036-8562, Japan

* Corresponding author. Tel: +81 172 39 5057; fax: +81 172 35 9190. E-mail address: taihei.itoh@gmail.com

Case report

A 43-year-old woman was referred for a frequent premature ventricular contraction (PVC) exhibiting a right bundle branch block and right inferior axis QRS morphology. The patient had undergone implantation of an implantable cardioverter-defibrillator due to symptomatic sick sinus syndrome and a strong family history of sudden cardiac death. The baseline atrio-His and His-ventricular intervals were 171 ms and 38 ms, respectively. During the PVC, activation mapping was performed in the left ventricle, revealing a Purkinje potential preceding the

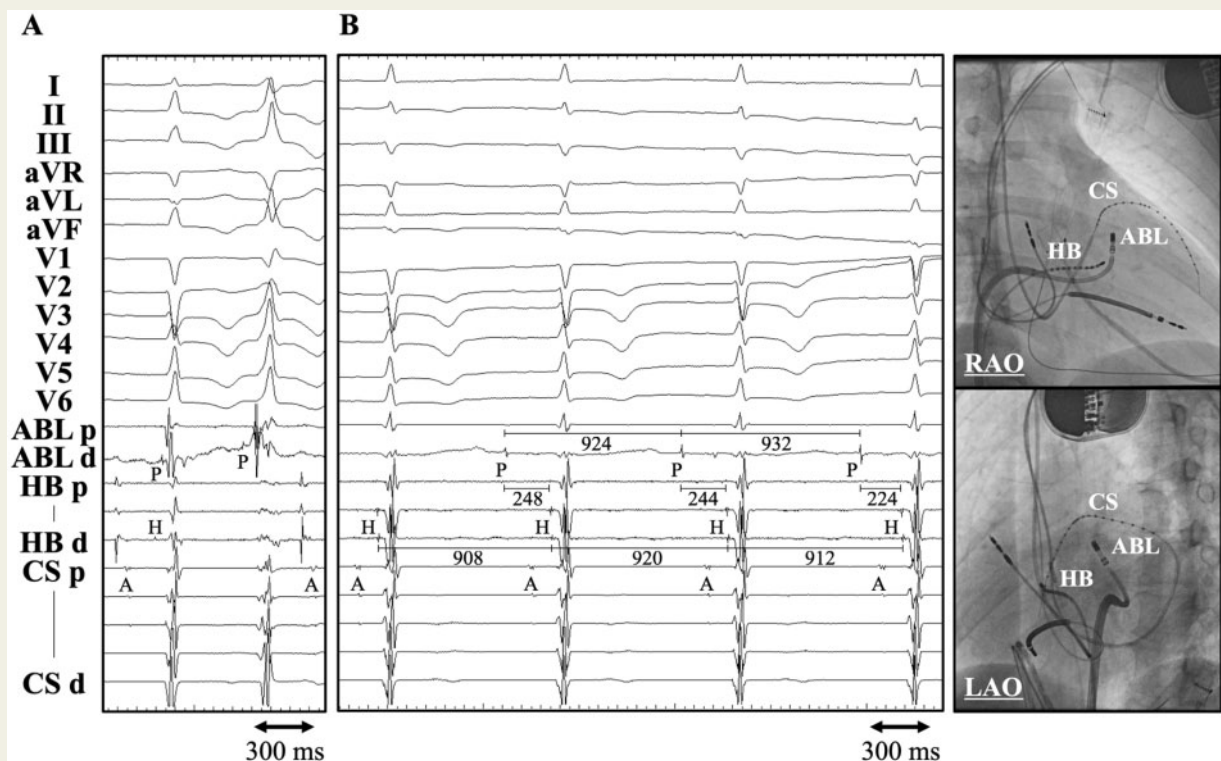


Figure 1 Cardiac tracings recorded at the first ablation site of the baseline premature ventricular contraction (A). Cardiac tracings recorded at the successful ablation site of the premature ventricular contraction occurring after the first ablation and fluoroscopic images exhibiting the successful ablation site (B). A, atrium; ABL, ablation catheter; CS, coronary sinus; HB, His (H) bundle; LAO, left anterior oblique; P, Purkinje potential; RAO, right anterior oblique; Xd, p, the distal and proximal electrode pairs of the relevant catheter.

QRS onset by 20 ms during sinus rhythm and by 72 ms during the PVC at the mid-anterolateral left ventricle (*Figure 1A*). A radiofrequency application at this site partially suppressed the PVC with a change in the QRS morphology exhibiting a deeper S wave in lead I and taller R waves in inferior leads (more of a right inferior axis pattern), leading to sinus QRS complexes with slight left axis deviation. Despite isoproterenol administration, the newly emerging PVC remained less frequent. However, further mapping at the basal side of the ablation site revealed isolated Purkinje potentials preceding the His-bundle (HB) electrogram by 224 to 248 ms during sinus rhythm (*Figure 1B*). There were no such isolated Purkinje activities at any other site in both ventricles during sinus rhythm. A couple of radiofrequency applications at that site induced Purkinje automaticity with the QRS morphology that was almost identical to that of the newly emerging PVC, resulting in complete elimination of the PVC and left anterior fascicle (LAF) block. At the first and successful ablation sites, pace mapping could not selectively capture the Purkinje system, and the pace maps were not excellent.

Discussion

A fascicular PVC can exhibit multiple QRS morphologies when a breakout site shifts from one fascicle to another spontaneously or after ablation at one breakout site. In this case, the first ablation at the mid-LAF induced this kind of a shift of a breakout site, and suppression of the PVC made precise activation mapping difficult. A recent study reported that before fascicular PVCs, conduction block between the PVC origin and ventricular myocardium could occur.¹ In this case, there were the successive interpolated Purkinje potentials between sinus beats at the proximal LAF, and the intervals of these Purkinje potentials were not driven by those of the preceding HB electrogram during sinus rhythm (*Figure 1B*). In addition, the ablation at that site successfully eliminated the PVC, with the induction of Purkinje automaticity exhibiting the QRS morphology that was almost identical to that of the breakout site-shifted PVC. Therefore, these findings suggested that the Purkinje activation derived not from sinus rhythm but from the PVC origin, and did not conduct through the Purkinje system to the distal LAF and the other fascicles.

This case demonstrated Purkinje-ventricle block between a fascicular PVC origin and the ventricular myocardium with no shift of the breakout site, presenting with interpolated Purkinje potentials during sinus rhythm.

Conflict of interest: none declared.

Reference

1. Itoh T, Yamada T. Multifocal ventricular arrhythmias originating from the His-Purkinje system: incidence, characteristics, and outcome of catheter ablation. *JACC Clin Electrophysiol* 2018;**4**:1248–60.